

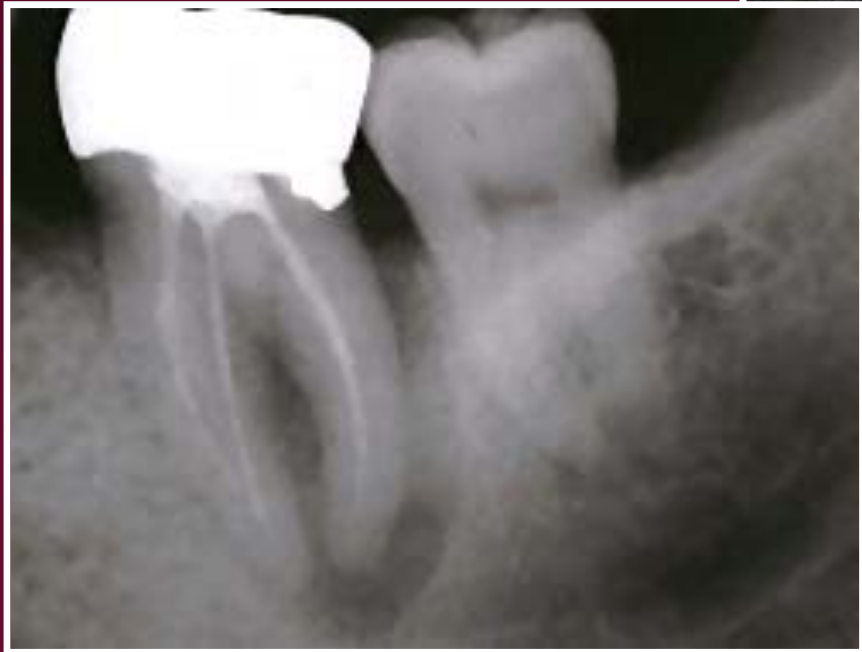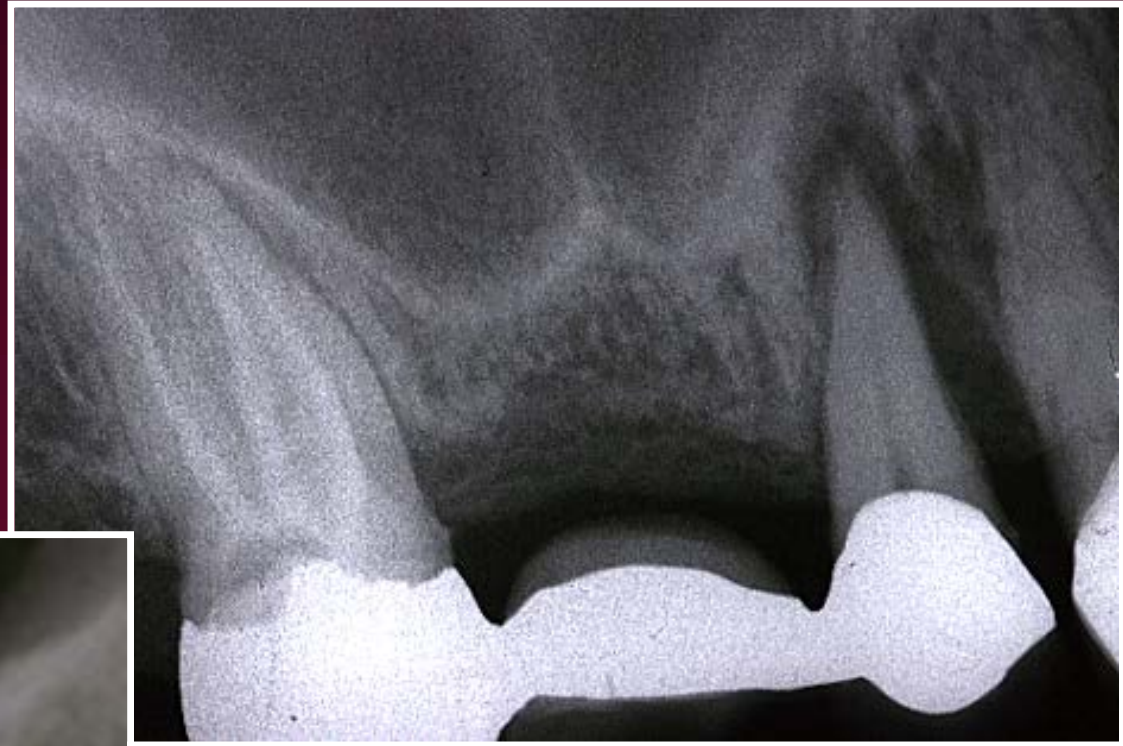Differential Diagnosis of Radiolucent Lesions of the Jaws

Widened Periodontal Ligament

- Endo/Perio Inflammatory Disease
- Traumatic Luxation
- Scleroderma
- Osteogenic Sarcoma



Endodontic/Periodontic Infection

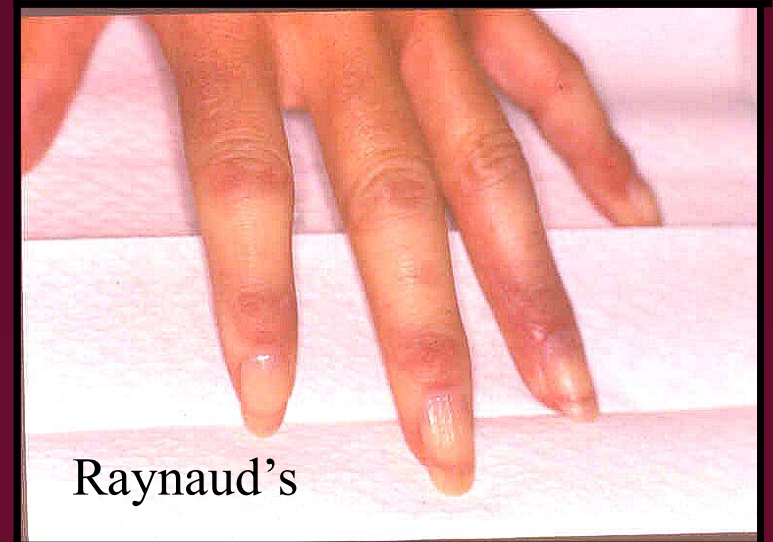
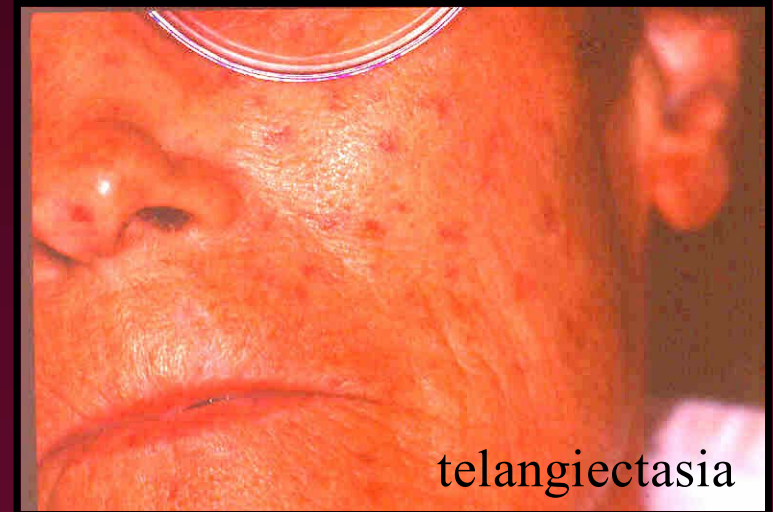
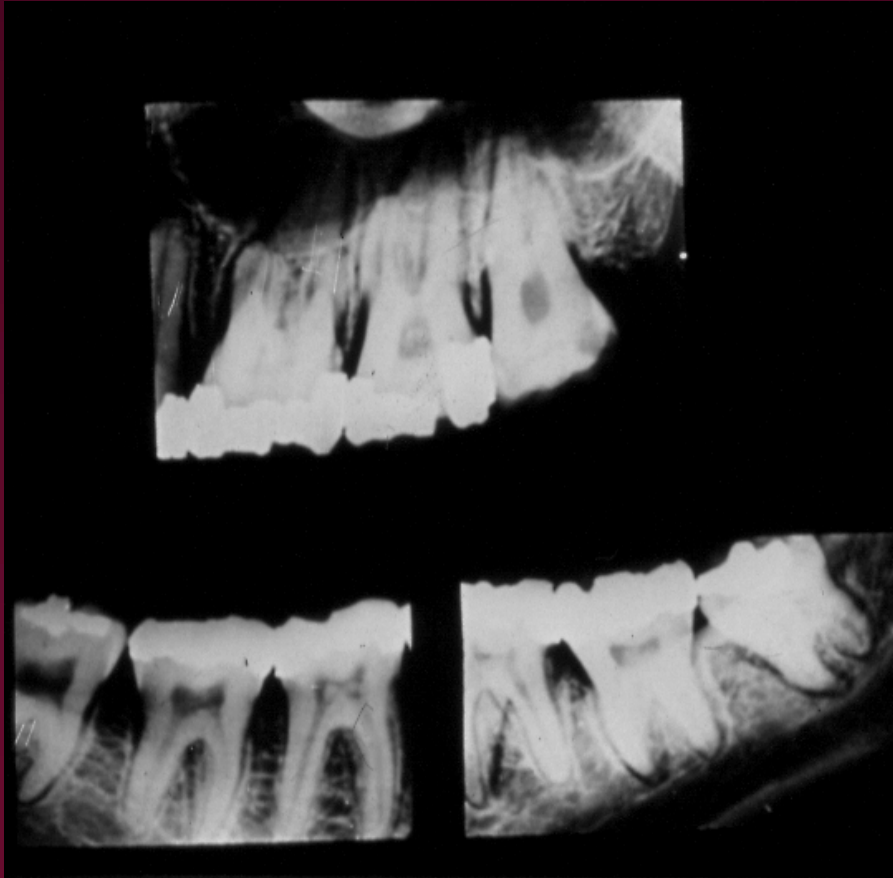Scleroderma

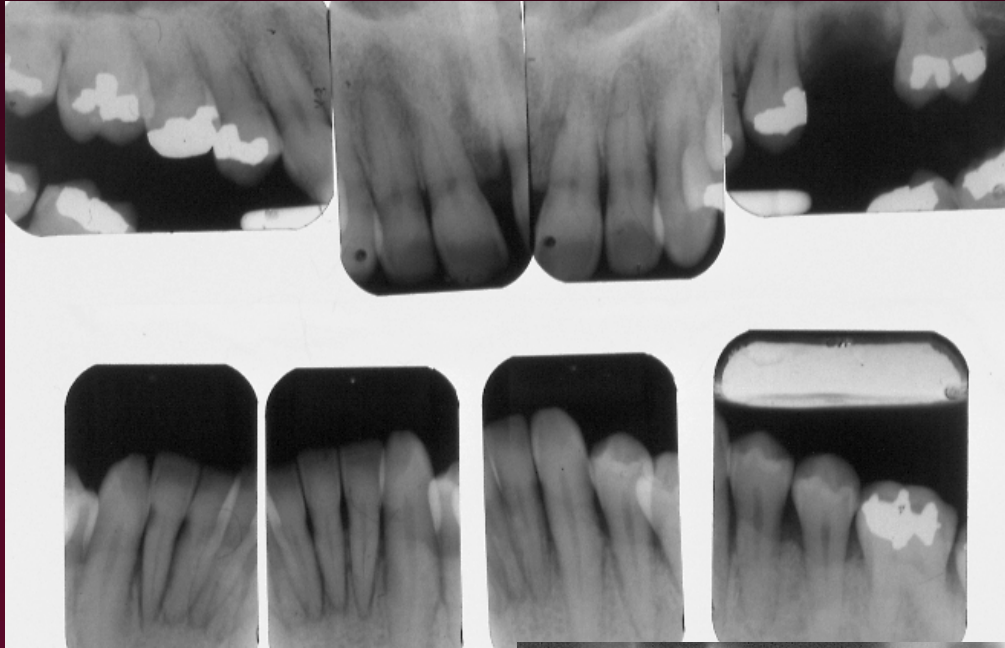- Systemic Sclerosis, Autoimmune
- Tightening of the skin
- Masklike facies
- CREST syndrome
 - Calcinosis, Raynaud's Phenomenon, Esophageal sclerosis, Telangiectasia
- Gonial angle erosions
- Gingival Recession
- Generalized Widened PDLs

Scleroderma

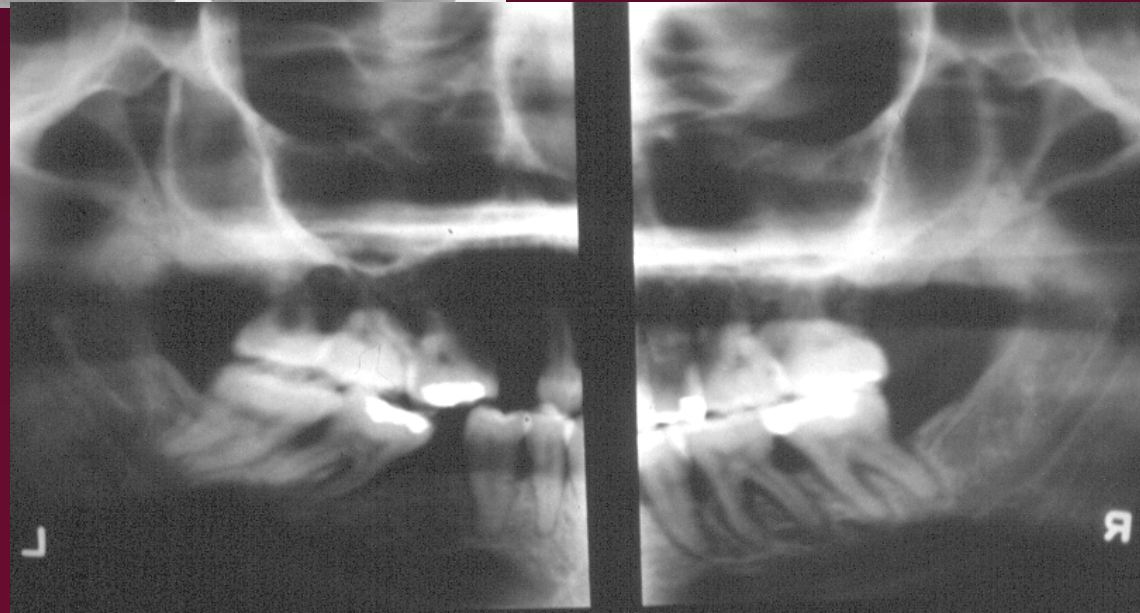- Generalized Wide PDL
- Clinical



Scleroderma



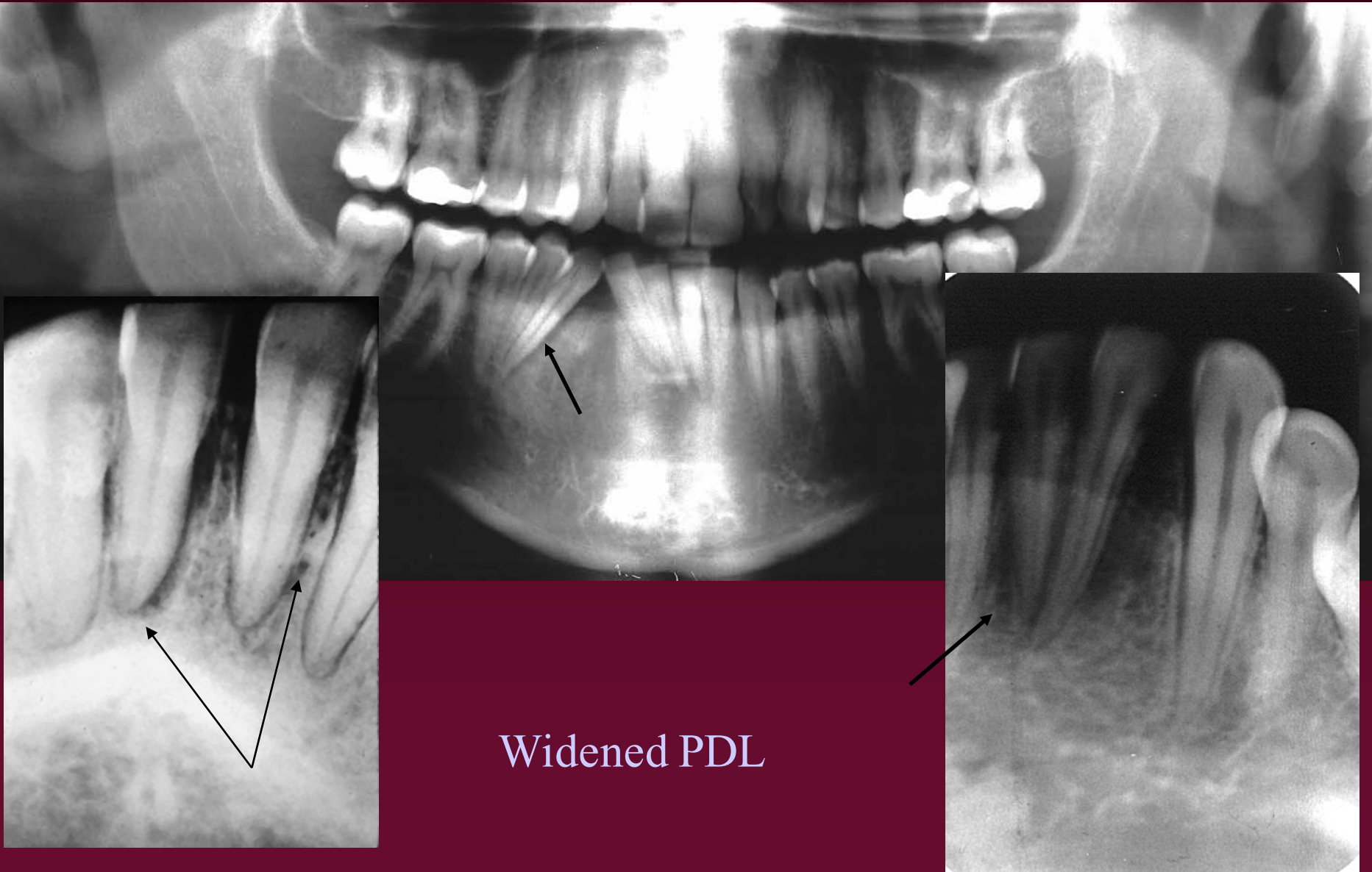
Widened PDL spaces



Osteogenic Sarcoma

- Double age peak
 - Young adults, Elderly adults
- Mandible > Maxilla
- Symmetrically widened PDL
- Poorly defined margins
 - Motheaten lucent, mixed lucent opaque, sunray effect (osteophytes)
- Histologic subtypes do not alter prognosis
 - Osteoblastic, Chondroblastic, Fibroblastic
- Histologic subtypes with an improved prognosis
 - Well differentiated, Juxtacortical, Parosteal

Osteogenic Sarcoma



Widened PDL

Osteogenic Sarcoma

Widened PDL

